



# Robotic Posterior Urethroplasty after Complete Urethral Transection During Abdominal Perineal Resection

Adam S. Baumgarten <sup>1</sup>, Kevin Heinsimer <sup>2</sup>, Lucas Wiegand <sup>1</sup>

<sup>1</sup> Department of Urology, University of South Florida, Tampa General Circle, Tampa, Florida, United States; <sup>2</sup> Department of Urology, USF Health Morsani College of Medicine, Tampa General Circle, Tampa, Florida, United States

## ABSTRACT

**Introduction and objective:** Urethral trauma after colorectal surgery is rare, and therefore, there is a paucity of literature on their management in the current era. Additionally, there is a lack of cases describing robotic posterior urethral repair without a simultaneous perineal dissection or history of prostate cancer treatment.

**Materials and methods:** Description of a robotic transabdominal posterior urethroplasty in a 39-year-old male with complete urethral transection after laparoscopic abdominal perineal resection (APR).

**Results:** The patient sustained complete urethral disruption while undergoing an APR. Imaging was consistent with urologic trauma limited to a urethral transection proximal to the membranous urethra. Three days after the APR, the patient was taken to the OR for repair. Prior port sites were utilized for our robotic port placement, the retropubic space was developed and dorsal venous complex divided similarly to a prostatectomy. After identifying the urethra with the aid of a cystoscope, the prostatic urethra was anastomosed to the membranous using a 3-0 barbed monofilament. At post-operative week four, a voiding cystourethrogram showed a small leak, therefore the urethral catheter was left for a total of six weeks. At last follow-up, the patient was voiding per urethra without fistula, incontinence, or stricture.

**Conclusions:** Early robotic repair of an iatrogenic posterior urethral disruption is feasible with successful short-term outcomes. This is a select and rare complication of colorectal surgery and therefore, long-term stricture free rates are yet to be determined.

## CONFLICT OF INTEREST

None declared.

## Correspondence address:

Adam S. Baumgarten, MD  
University of South Florida - Urology 2,  
Tampa General Circle, Tampa  
Florida, 33620-9951, United States  
E-mail: abaumgar@health.usf.edu

## ARTICLE INFO

 Adam S. Baumgarten  
<https://orcid.org/0000-0001-8042-7036>

**Available at:** [http://www.int brazjurol.com.br/video-section/20190425\\_Baumgarten\\_et\\_al](http://www.int brazjurol.com.br/video-section/20190425_Baumgarten_et_al)  
**Int Braz J Urol. 2021; 47 (Video #1): 210**

Submitted for publication:  
June 27, 2019

Accepted after revision:  
April 04, 2020

Published as Ahead of Print:  
September 02, 2020



## Female sling: handmade adjustable threads

Luis Gustavo Morato de Toledo <sup>1</sup>, Rafael Ribeiro Zanotti <sup>1</sup>, André Costa Matos <sup>2</sup>

<sup>1</sup> Seção de Urologia do Departamento de Cirurgia da Faculdade de Ciências Médicas da Santa Casa de São Paulo, SP, Brasil; <sup>2</sup> Departamento de Urologia, Hospital São Rafael - Rede D'or, BA, Brasil

### ABSTRACT

**Introduction:** The optimal fit of a sling mesh for the treatment of stress urinary incontinence (SUI) in patients with associated pelvic organ prolapse (POP), or other predictors of sling failure, such as fixed urethra and previous incontinence surgery, can be challenging. The ideal point of tension may not be accurate, when the tape is too loose, incontinence persists. On the other hand, when the tape is too tight, urinary obstruction is produced. For these patients, adjustable slings are desirable.

**Objective:** The purpose of this article and accompanying video is to show that synthetic middle urethral slings can be adjustable if necessary.

**Materials and Methods:** In our report and accompanying video, we demonstrate and explain the technique to make handmade adjustable sling threads. The selected tape was an Obtryx Halo™, but the technique can be employed to any synthetic middle urethral sling, retropubic or transobturator. We also show the adjustments at the post-operative days. That patient underwent colpocleisis and transobturator sling. On first postoperative day, before removal of the catheter, bladder is filled with 200 to 300mL of saline solution. After catheter removal, cough stress test is performed and if leakage occurs, the sling is tightened (Figure-1). Complete emptying must be certified by post-voiding catheterization, especially if tightening has been performed. In case of over tensioning, the suture for loosening may be used (Figure-2). The patient is discharged from the hospital after optimal adjustment of the sling tension has been obtained. Early outpatient returns are scheduled for stress and voiding testing, and so, new adjustments if necessary. Adjustment sutures are removed 3 to 7 days after the last adjustment. Sling adjustment is painful, local anesthesia may be applied to the sling path through the skin. The patient is maintained on antibiotic prophylaxis with cephalosporin until the adjustable sutures are removed.

**Results:** The patient was maintained catheterized for 24 hours and discharged at first post-operative day, when we did the first tightening adjustment. Another adjustment was necessary at outpatient follow-up on sixth post-operative day. She was dry on tenth post-operative day, without urinary residual and with normal uroflowmetry parameters; so, we cut out the threads. The patient had no recurrence of genital prolapse and no leakage, she was fully satisfied one year after surgery.

**Conclusions:** Synthetic middle urethral slings can become adjustable for the first 7 to 10 post-operative days. Late displacement of the sling can be too painful and is not recommended. The adjustment will benefit a restrict number of patients with poor prognosis factors (urethral hypomobility, advanced stage POP, previous SUI surgery, detrusor underactivity), when the successful sling tensioning range is narrow (Figure-3). It can prevent immediate failure for this group of patients. This procedure represents a safe, effective, and low-cost technique for SUI treatment, and does not increase the risk of infection nor erosion or other negative effect.

### CONFLICT OF INTEREST

None declared.

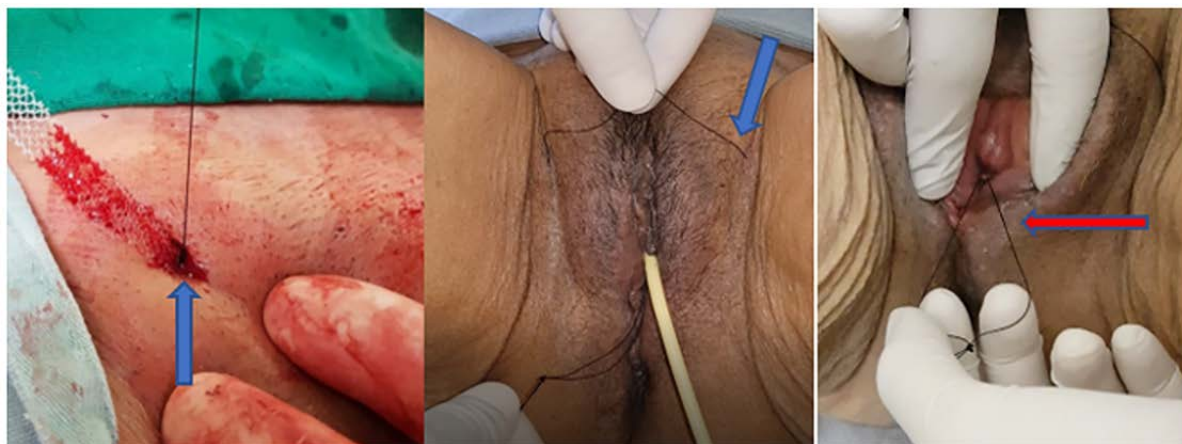## ARTICLE INFO

 **Luis Gustavo Morato de Toledo**

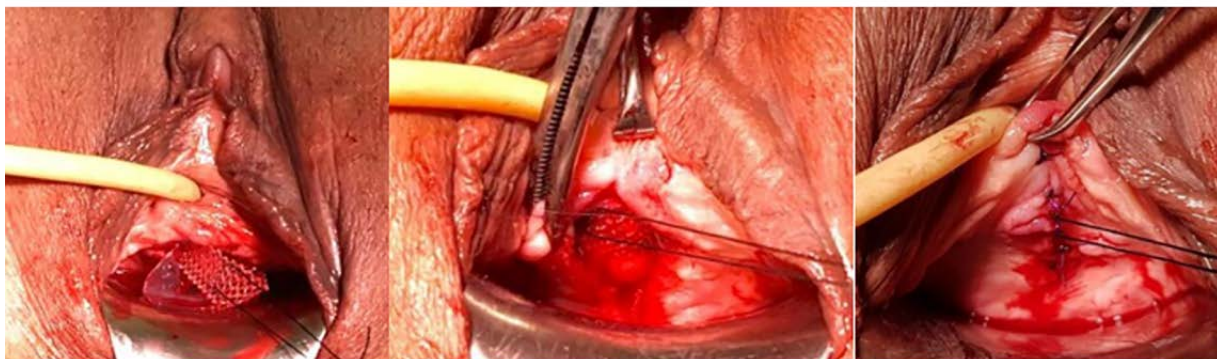
<https://orcid.org/0000-0003-2304-9336>

Available at: [http://www.int brazjurol.com.br/video-section/20190432\\_Zanotti\\_et\\_al](http://www.int brazjurol.com.br/video-section/20190432_Zanotti_et_al)  
Int Braz J Urol. 2021; 47 (Video #2): 211-3

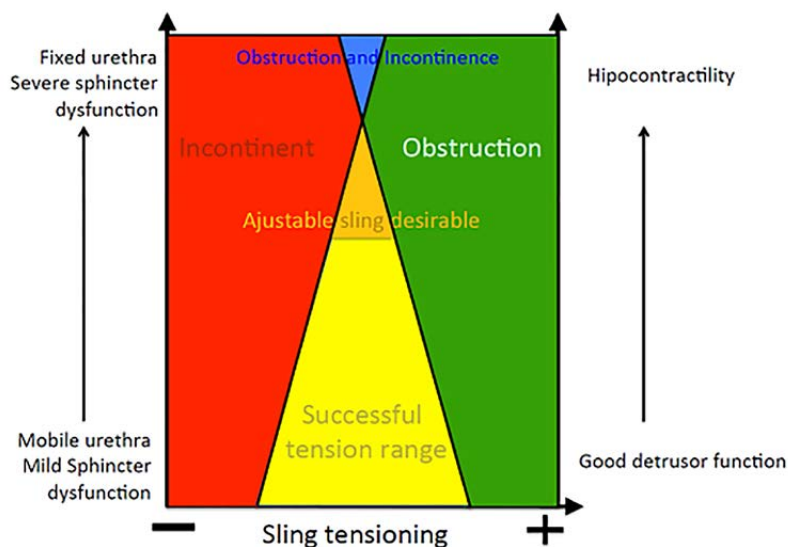
**Figure 1 - Blue arrow: retropubic (left) and transobturator (middle) threads for tightening, red arrow: thread for loosening.**



**Figure 2 - Central thread for loosening. Positioned 1-2cm laterally to the urethral midline, so the mesh does not come out through the vaginal suture if loosening is necessary.**



**Figure 3 - Diagram showing different patient presentations, at the bottom we have patients with good urethral mobility, mild sphincter dysfunction and good detrusor function; therefore, a wide range of successful sling tensioning. As you go up towards the patients tending to severe sphincter dysfunction, detrusor underactivity and fixed urethra, the successful range gets progressively narrower, so in this occasion the adjustable sling is desirable.**



## REFERENCES

1. Shkarupa D, Kubin N, Staroseltseva O, Shapovalova E. Adjustable transobturator sling for the treatment of primary stress urinary incontinence. *Int Urogynecol J.* 2018;29:1341-1347.
2. Borazjani A, Pizarro-Berdichevsky J, Li J, Goldman HB. Erratum to: Surgeons' views on sling tensioning during surgery for female stress urinary incontinence. *Int Urogynecol J.* 2017;28:1497-1498.
3. Patrelli TS, Gizzo S, Noventa M, Dall'Asta A, Musarò A, Faioli R, et al. Female stress urinary incontinence: clinical efficacy and satisfaction after transobturator adjustable tape sling. An observational longitudinal cohort study. *Surg Innov.* 2015;22:137-42.
4. Maroto JR, Gorraiz MO, Bueno JJ, Pérez LG, Bru JJ, Chaparro LP. Transobturator adjustable tape (TOA) permits to correct postoperatively the tension applied in stress incontinence surgery. *Int Urogynecol J Pelvic Floor Dysfunct.* 2009;20:797-805.

Submitted for publication:  
July 01, 2019

Accepted after revision:  
March 24, 2020

Published as Ahead of Print:  
September 10, 2020

## Correspondence address:

Rafael Ribeiro Zanotti  
Chefe do Departamento de Urologia,  
Departamento de Cirurgia, Irmandade da  
Santa Casa de São Paulo, SP, Brasil  
E-mail: rafael\_r\_z@hotmail.com