



Whole muscle ^{18}F -choline uptake due to intense physical exercise

Francisco Javier García-Gómez¹, Pablo Antonio de la Riva-Pérez¹, Ana Agudo-Martínez¹, Gertrudis Sabatel-Hernández¹, María Cinta Calvo-Morón¹

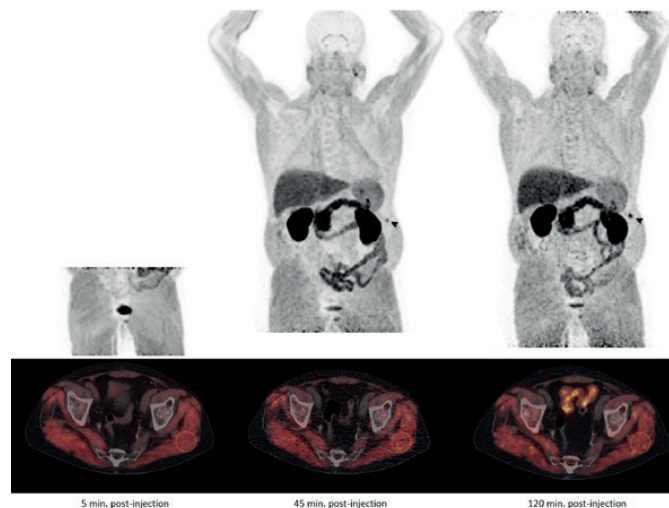
¹ Department of Nuclear Medicine, Virgen Macarena University Hospital, Seville, Spain

INTRODUCTION

We report an ^{18}F -choline PET/CT scan performed on a 74-year-old patient with history of prostate neoplasm in the clinical context of progressive PSA elevation (10ng/ml) with negative imaging tests. Pelvic images were acquired at 5 min. post-injection of standardized radiotracer dose, while whole-body images were obtained 45 and 120 min. after injection (Figure-1; MIP images). A homogeneous increased uptake of tracer in the whole axial and appendicular muscle structures was highlighted in all series. A SUV_{max} of 4.8, 5.0 and 4.9 were reached in a reference ROI at left gluteus maximus muscle (Figure-1; axial fused images).

Additionally, a fracture of the eleventh left rib arch was also observed (head-arrow). An intense basal physical activity mainly based on long walks, farming tasks and dance classes were referred when the patient was re-interrogated. Taking medication that might interfere with tracer distribution, such as colchicine (1), was also ruled out. It is well known that ^{18}F -choline can be uptake in different tissues including striated muscle (2, 3), although it is a poor referred finding which seems to be related to physical activity, being most likely due to increased local perfusion and probably unavoidable to some extent (3). Knowledge of these variability of physiological uptake, benign findings and pitfalls, is crucial in order to get the most out of the scan.

Figure 1 - MIP and fused PET/CT images acquired at 5 min, 45 min and 120 min after intravenous injection of ^{18}F -Choline. An intense and diffuse uptake of radiotracer was observed in all the series of the study. The muscle activity was measured by circular ROI in gluteus maximus muscle (axial fused images) demonstrating stable activity throughout the exploration. Incidentally, a fracture of the eleventh left rib arch was also observed (head-arrow).



REFERENCES

1. Roef MJ, van der Poel H, van der Laken CJ, Vogel WV. Colchicine must be stopped before imaging with [18F]-methylcholine PET/CT. *Nucl Med Commun.* 2010;31:1075-7.
2. Beheshti M, Haroon A, Bomanji JB, Langsteger W. Fluorocholine PET/computed tomography: physiologic uptake, benign findings, and pitfalls. *PET Clin.* 2014;9:299-306.
3. Roef M, Vogel WV. The effects of muscle exercise and bed rest on [18F]methylcholine PET/CT. *Eur J Nucl Med Mol Imaging.* 2011;38:526-30.

Correspondence address:

Francisco Javier García-Gómez, MD
Department of Nuclear Medicine
Virgen Macarena University Hospital
Av. Dr. Fedriani 3
41009, Seville, Spain
Fax: + 34 95 500-9162
E-mail: javier191185@gmail.com

ARTICLE INFO

 **Francisco Javier Garcia Gomez**
<https://orcid.org/0000-0001-9307-5017>

Int Braz J Urol. 2019; 45: 851-2

Submitted for publication:
August 16, 2018

Accepted after revision:
February 18, 2019

Published as Ahead of Print:
April 10, 2019