



Robotic assisted radical nephrectomy with Inferior vena cava tumor thrombus

Maxwell Sandberg ¹, Wyatt Whitman ¹, Alejandro Rodriguez ¹

¹ Department of Urology, Wake Forest School of Medicine, Medical Center Boulevard, Winston Salem, NC, USA

ABSTRACT

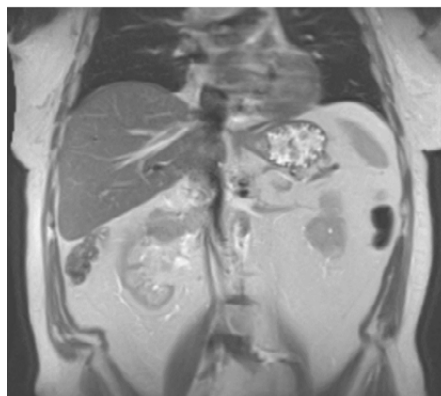Purpose: Surgery for renal cell carcinoma (RCC) with an inferior vena cava (IVC) tumor thrombus can be done via a robotic approach. While this approach is thought to minimize blood loss, it may still result in significant losses (1) and current publications indicate that it can require upwards of 3-day hospital stays (1, 2). However, innovative surgical techniques, such as the split and roll, may curtail this. The purpose of this video is to present the case and surgical technique of robotic assisted radical nephrectomy with IVC thrombectomy.

Materials and Methods: The patient was a 77-year-old male found to have a right upper pole renal mass on CT urogram. On MRI (Figure 1), a renal mass and level II thrombus was seen. For this case, the Da Vinci Xi Intuitive robotic system was used, with four robotic 8-millimeter (mm) metallic trocars, two 5 mm assistant trocars, and one 12 mm air seal port. The split and roll technique were utilized to access the IVC and lumbar veins. This surgical method uses the adventitia of the IVC as a plane of dissection and safely identifies all branches/tributaries of the IVC to minimize the chance of vascular injury (3).

Results: Robotic console time was 150 minutes. The patient had an excellent outcome, with all tumor thrombus removed, less than 50cc of blood loss, and was discharged within 24 hours of the operation. The tumor pathology came back as papillary, high grade, and was stage pT3bN1.

Conclusions: The robotic approach with split and roll technique is a great surgical option for urologists to consider in patients with RCC and a level I or II thrombus, which can minimize blood loss and expedite discharge.

Figure 1 - MRI of abdomen.



On an axial view of the abdomen, the level II thrombus was seen pre-operatively. This was determined to be a level II thrombus.

CONFLICT OF INTEREST

None declared.

REFERENCES

1. Pulford C, Keating K, Rohloff M, Peifer D, Eames R, Shakuri-Rad J, et al. Robotic-assisted nephrectomy with level II IVC thrombectomy using Rummel Tourniquets. *Int Braz J Urol.* 2022;48:196-7.
2. Ahluwalia P, Tamhankar A, Gautam G. Robotic radical nephrectomy and level II inferior vena cava thrombectomy: exploring the newer frontiers. *Int Braz J Urol.* 2021;47:218-9.
3. Tran V, Gibson L, Sengupta S. Retroperitoneal lymph node dissection for germ cell tumour. *Transl Androl Urol.* 2020;9:3103-11.


Correspondence address:
Alejandro Rodriguez, MD
Department of Urology,
Wake Forest School of Medicine,
Medical Center Boulevard,
Winston Salem, NC, 27157, USA
E-mail: alrrodri@wakehealth.edu

Submitted for publication:
May 29, 2023

Accepted after revision:
June 21, 2023

Published as Ahead of Print:
July 20, 2023

ARTICLE INFO

 **Maxwell Sandberg**
<https://orcid.org/0000-0003-2880-1857>

Available at: http://www.intbrazjurol.com.br/video-section/20230245_Rodriguez_et_al
Int Braz J Urol. 2023; 49 (Video #12): 650-1